

# Chronic Headaches in Adolescents; A Case Study

## History.

A 15 year old female presented with chronic headaches of six months duration. She stated the pain was located across the forehead at moderate intensity which was constant throughout the day. It was not alleviated by analgesics or other physical therapeutic modalities. The patient was unable to attend school during this time. She also noted changes in mood and concentration along with difficulties in language and sequential planning . She had previously been diagnosed with Chronic Fatigue Syndrome two years earlier.

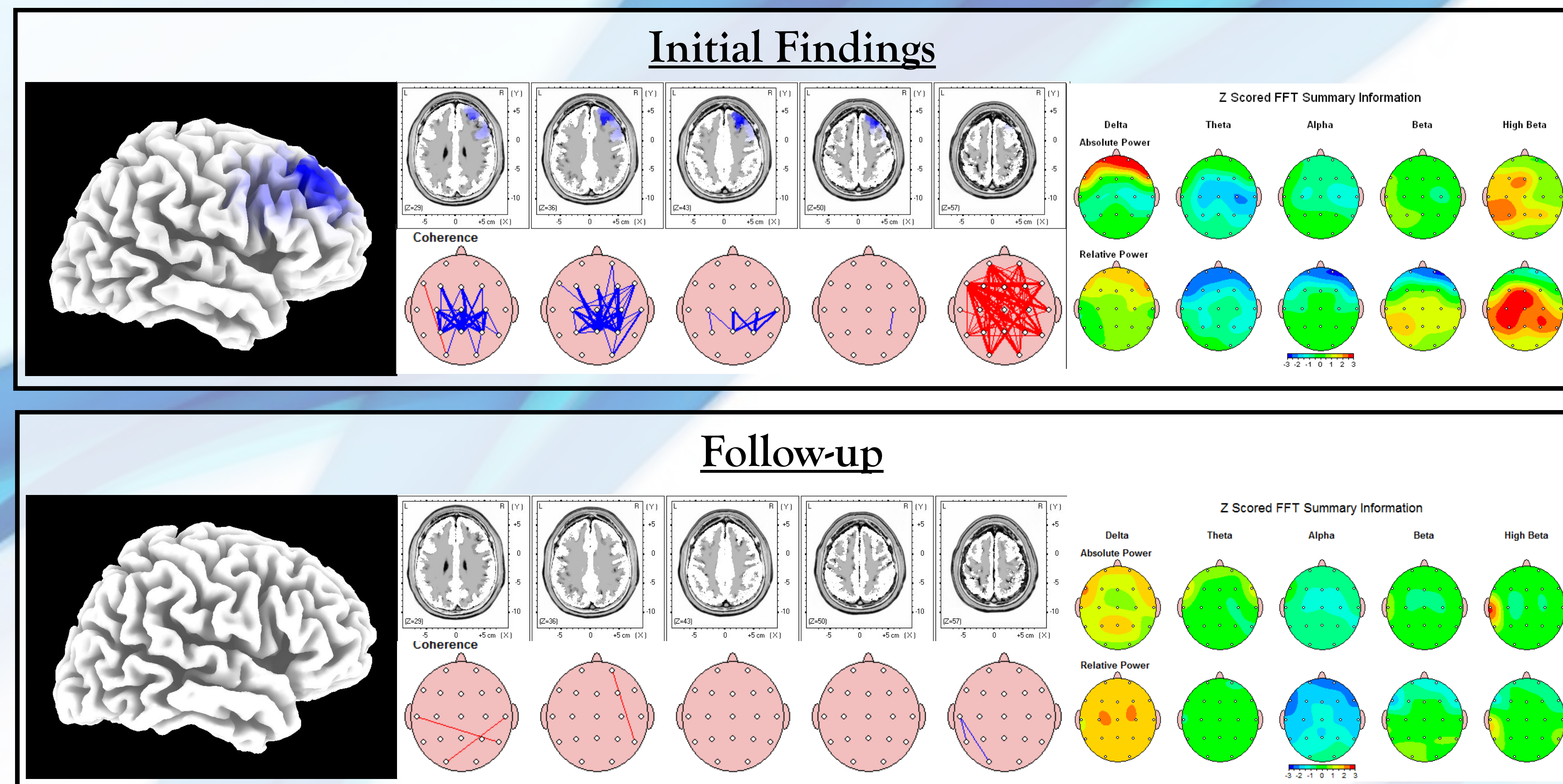
## Physical Exam

The physical exam was unable to reveal any pathological findings. A cranial nerve and motor-sensory examination were performed with no abnormalities found.

## Initial Finding

Initial qEEG and LORETA analysis showed hypercoherence throughout the cortex in the high beta frequency. There was also hypocoherece in the delta and theta frequencies in the cortex centrally. Primary findings include a decrease in activity in the frontal cortex across most frequencies more significantly located on the right side. In addition there was hyperactivation in the left parietal cortex most prominently but not limited to theta frequencies.

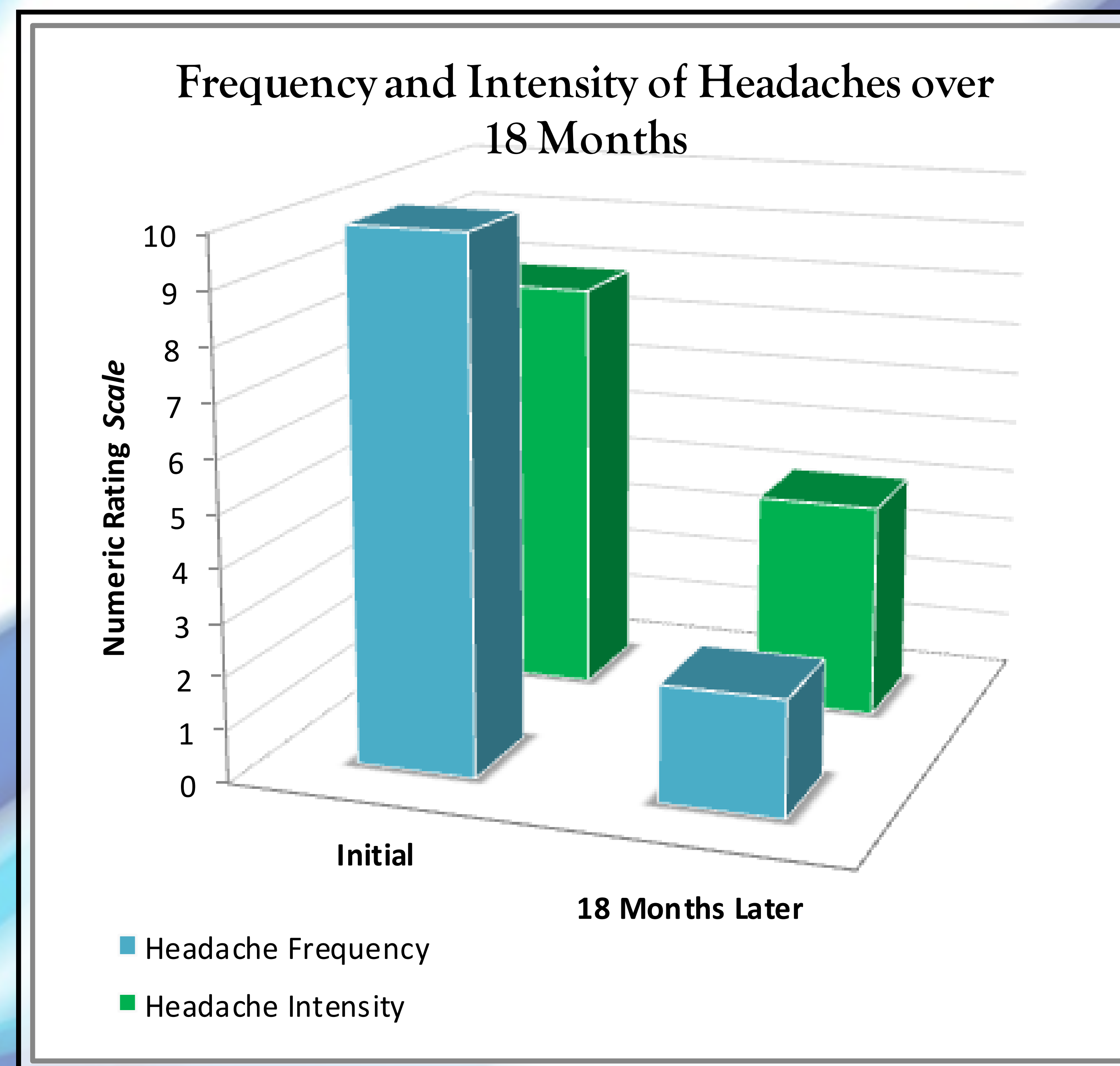
The LORETA analysis showing the frontal cortex hypoactivation was specifically located in Brodmann areas eight and nine. These areas are typically associated with eye movements, thought, cognition and planning.



## Follow up Findings

The Quantitative electroencephalographic (qEEG) examination and LORETA analysis show good coherence across all frequencies. Activity levels throughout the brain show marginal hypo activity in the frontal cortex in the alpha frequencies. There is also marginal increase in activity throughout the cortex globally in the delta frequency.

LORETA analysis was unable to show any dysfunction in Brodmann areas eight and nine under the same conditions measured previously.

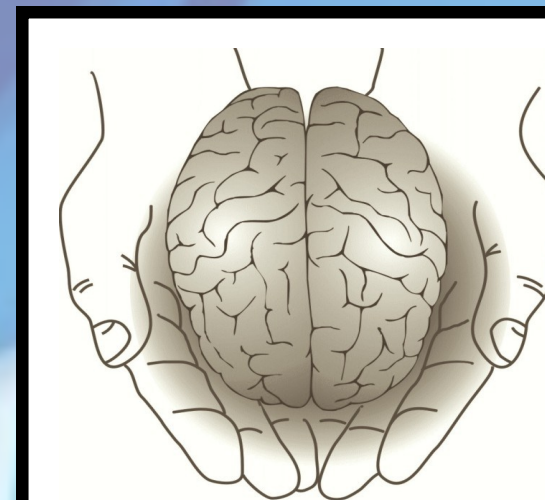

## Conclusion

18 months following the initial examination, the qEEG and LORETA analysis show a significant improvement across all areas of concern. There was significant normalisation of the coherence across all frequencies. The qEEG also showed increased activation in the frontal cortex across alpha, beta and theta frequencies when compared against previous data.

The patient was asked to record a headache diary which measured frequency and intensity of each headache episode. When comparing the data initially against follow-up there was a significant improvement in both areas. There was a reduction in frequency by 77% (99% to 22%) and intensity reduced by 38% (79% to 41%).

Furthermore, the patient was able to return to distance education after 6 months of treatment with improved concentration, sequential planning and language skills.



**Institute of  
Functional Neuroscience**

By: Dr Daniel Ward BSc , B Chiro